

Effects of the Lexington LaserComb on hair regrowth in the C3H/HeJ mouse model of alopecia areata

Tongyu Cao · Wikramanayake · Rosa Rodriguez ·
Sonal Choudhary · Lucia M. Mauro · Keyvan Nouri ·
Lawrence A. Schachner · Joaquin J. Jimenez

Received: 18 January 2011 / Accepted: 20 June 2011
© Springer-Verlag London Ltd 2011

Abstract Alopecia areata (AA) is a common autoimmune disease that presents with non-scarring alopecia. It is characterized by intra- or peri-follicular lymphocytic infiltrates composed of CD4⁺ and CD8⁺ T-cells on histology. To this day, few treatments are effective for AA. Here we present findings of using a low-level laser comb to alleviate the symptoms of AA in a C3H/HeJ mouse model for AA. Fourteen C3H/HeJ mice with induced AA were used in this study. Two were killed to confirm AA through histology. The remaining 12 mice were randomized into two groups; group I received HairMax LaserComb (wavelength: 655 nm, beam diameter <5 mm; divergence 57 mrad; nine lasers) for 20 s daily, three times per week for a total of 6 weeks; group II was treated similarly, except that the laser

was turned off (sham-treated). After 6 weeks of LaserComb treatment, hair regrowth was observed in all the mice in group I (laser-treated) but none in group II (sham-treated). On histology, increased number of anagen hair follicles was observed in laser-treated mice. On the other hand, sham-treated mice demonstrated hair follicles in the telogen phase with no hair shaft. LaserComb seems to be an effective and convenient device for the treatment of AA in the C3H/HeJ mouse model. Human studies are required to determine the efficacy and safety of this device for AA therapy.

Keywords LaserComb · 655-nm laser · Alopecia areata · C3H/HeJ mice

T. C. Wikramanayake · R. Rodriguez · L. A. Schachner ·
J. J. Jimenez (✉)
Department of Dermatology and Cutaneous Surgery,
University of Miami, Miller School of Medicine,
1600 NW 10th Avenue, RSMB 2023A,
Miami, FL 33136, USA
e-mail: jjimenez@med.miami.edu

R. Rodriguez
Laboratory of Kidney and Electrolyte Metabolism, National
Heart, Lung and Blood Institute, National Institutes of Health,
Bethesda, MD, USA

S. Choudhary · K. Nouri
Department of Dermatology and Cutaneous Surgery,
University of Miami, Miller School of Medicine,
1475 NW 12th Avenue, Suite# 2175,
Miami, FL 33136, USA

L. M. Mauro
Department of Biochemistry and Molecular Biology,
University of Miami, Miller School of Medicine,
1011 NW 15th Street, Gautier 328,
Miami, FL 33136, USA

Introduction

Alopecia areata (AA) is a common autoimmune disease characterized by well-defined patches of non-scarring hair loss that can occur on virtually any hair-bearing area, but most commonly involves the scalp (approximately 90% of AA cases seen in dermatologic clinics) [1]. The worldwide frequency of AA has been estimated to range from 0.7–3.8% [2, 3], while in the United States approximately 0.1–0.2% of the general population is affected by AA [4], with a lifetime risk of 1.7% [5]. The extent of disease has been used to classify AA into patchy AA (partial loss of scalp hair); alopecia totalis (AT) (100% loss of scalp hair) and alopecia universalis (AU) (100% loss of scalp and body hair). Approximately 5% of AA cases progress to AT/AU [6]. The extent of hair loss is believed to be the most important prognostic factor for the disease [3]. The other markers indicating poor prognosis for AA are Ophiasis pattern of hair loss (band-like hair loss in the parieto-temporo-occipital area) [2], prolonged duration of hair loss

[2], atopy, a positive family history, the presence of other autoimmune diseases, nail involvement and a young age at first presentation [7]. AA often results in significant psychological distress, especially when it involves children, teenagers, and young adults.

The hair-pull test in AA may demonstrate some dystrophic anagen hairs (compared to only telogen hairs seen in telogen effluvium). Clinically, the skin surface over the alopecia patches in AA may appear "peachy" [7] or slightly red in color [8] with presence of short hairs tapered proximally and wider distally known as "exclamation hairs". Videodermoscopy is a useful non-invasive tool to aid in the diagnosis of AA where the expected findings are yellow dots (follicular openings filled with keratinous debris mixed with sebum) and short regrowing hairs [9]. Scalp biopsy in acute AA demonstrates a peribulbar lymphocytic and eosinophilic infiltrate [10]. In subacute cases, large numbers of catagen and telogen hairs are seen, with catagen/telogen exceeding 50% of the total follicles [11, 12]. Although an uncommon event, focal matrix cell vacuolization is also a feature of AA [12]. Ahmed et al. and Whiting in separate studies demonstrated that there is an increase in telogen hairs in the acute and chronic stages of AA whereas catagen hairs increased markedly in sub-acute stage [11, 13]. Miniaturized (atrophic) follicle is more frequently a feature of chronic stage, while it is absent in acute and sub-acute stages. The degree of peribulbar infiltration of lymphocytes varies with the stage of AA as well, with dense infiltrates seen in acute stage, mild to moderate infiltration in sub-acute stage, and minimal or no infiltrations observed in chronic stage. The authors also suggested that AA can be diagnosed even in the absence of inflammatory infiltrate, based on increased numbers of telogen hairs in the acute and chronic stages, increased miniaturized hairs in chronic stage and markedly increased catagen hairs in the sub-acute stage.

The normal hair follicle immune system has a very low MHC class I antigens expression and absence of MHC class II antigens expression in the proximal epithelium of anagen hair follicle in all mammalian species that have been studied, including humans [14–16]. In addition, the anagen hair follicle cells are believed to actively suppress the activity of natural killer (NK) cells, preventing their constant attack on the cells that express low levels of MHC class I molecules [17]. Furthermore, TGF- β 1 and α -melanocyte stimulating hormone (MSH), which are potent immunosuppressants, are expressed in the proximal anagen hair follicle [18], and the Langerhans cells detected in this region are non-functional [16]. Thus, the hair follicle possesses an immune privilege, which is believed to be lost in AA, thereby exposing the hair follicle to immune attack via antigen presentation, co-stimulation and activation of responsive CD4⁺ and CD8⁺ cells. Subsequently, an

inflammatory response occurs in the peribulbar and bulbar sections of the hair follicle. Inflammatory infiltrates are highly disruptive to the hair follicles. Multiple cytokines and other molecules involved in the cyclic hair growth have been shown to play a role in the pathogenesis of AA. These include IFN- γ [19], IL-1 α and β [20], TNF- α [21], MHC and Fas-antigen [22, 23], and macrophage migration inhibitory factor [24]. In this regard, the hair cycle in AA patients is abnormal, with premature conversion of anagen to telogen and/or a dystrophic anagen [25].

AA spares the stem cells and attacks only the base of the hair follicle. There is no permanent organ destruction, and hair regrowth is possible [26], yet it is sometimes difficult for severe cases to respond to treatment. The most effective therapeutic agents that have been tested in clinical trials on human AA patients have been classified as: contact sensitizers [diphencyprone (DPCP), squaric acid dibutylester (SADBE), dinitrochlorobenzene (DNCB)]; immunosuppressive agents [cyclosporine A, Tacrolimus, Anthralin, Corticosteroids, Interferons]; monoclonal antibodies that block specific molecular pathways; alkylating agents [Meclorethamine] and hair growth promoters [Minoxidil, Gonadal steroid hormone regulator agents].

Animal models are important tools in the investigation of genetic and environmental pathogenic factors, and in the development of novel treatments. Two of the most studied rodent models for AA are the C3H/HeJ mice and Dundee Experimental Bald Rats (DEBR) [27, 28]. Up to 20% of aged C3H/HeJ mice and 70% of DEBR develop AA. These murine models have been employed in determining the genetic basis of AA, understanding the immunological mechanisms of disease initiation and progression, as well as testing the mechanism and efficacy of drugs [29, 30]. More recently, it has been demonstrated that hair loss can be induced prematurely and with a higher incidence by topical, focal heat application in C3H/HeJ mice, wherein histological analysis detected AA characteristics such as intra- and peri-follicular mononuclear cell infiltration in anagen hair follicles [31].

The low-level laser therapy device, LaserComb[®], has been cleared by the FDA to treat androgenetic alopecia (AGA), providing a home therapeutic approach [32]. The HairMax LaserComb[®] (Lexington International, LLC) is a hand-held device designated as class 3R low-level laser (LLL) therapy. It emits nine beams at a wavelength of 655 nm (\pm 5%). The LLL in skin has been shown to be in the red and infra-red spectrum (650–950 nm), thus making the 655-nm wavelength of the LaserComb quite effective. The device has attached combs on it that help to part the hairs and improve the delivery of laser light to the scalp. Each of the teeth on the combs aligns with a laser beam, resulting in easy and unobstructed delivery of laser beam to the area being treated.

Based on the successful hair regrowth documented in a previous clinical trial for male AGA with the HairMax LaserComb device, we postulated that the LaserComb might be used as an alternative treatment for AA [32]. To test this hypothesis, we treated C3H/HeJ mice with induced AA with LaserComb and measured the outcomes clinically and histologically.

Materials and methods

All animal care and use procedures were approved by the University of Miami Institutional Animal Care and Use Committee (IACUC). Retired female C3H/HeJ breeders were purchased from the Jackson Laboratory (Bar Harbor, ME). Mice were given rodent chow and water ad libitum. AA was induced in 14, 8-month-old female C3H/HeJ mice by localized heat treatment as previously described [31]. AA was confirmed histologically in skin biopsies from two mice. The remaining 12 mice were randomized into two groups: group I was treated with the HairMax LaserComb (wavelength: 655 nm, beam diameter <5 mm; divergence 57 mrad; nine lasers) for 20 s daily, three times per week for a total of 6 weeks; group II was treated similarly, but with the laser off (sham-treated). Skin samples were collected from the dorsum of a laser-treated mouse and a sham-treated mouse, and fixed in 10% formalin. Paraffin embedded sections (5 μ m) were stained with hematoxylin and eosin (H&E), and evaluated under a microscope (Carl Zeiss Microimaging LLC, Thornwood, NY).

Results

Of the 14 mice included in the study, two were used for confirming the AA phenotype. The remaining 12 mice were divided into two groups, those treated with LaserComb (group I) and those sham-treated (group II), and monitored for hair regrowth. Hair regrowth was first observed in group I, 2 weeks after initiation of laser treatment (Fig. 1b). At 6 weeks there was complete regrowth of hair in the alopecic lesion (Fig. 1c) in all six mice in group I. In contrast, mice in group II exhibited no regrowth of hair (data not shown).

Histopathology with H&E staining confirmed the gross findings. After 6 weeks of the LaserComb treatment (group I) (Fig. 2b), an increase in the number of hair follicles was observed in the subcutaneous layer, the majority of which were in the anagen phase, though some had entered the catagen phase. The anagen hair bulbs were larger compared to the sham-treated mice (group II) in whom the majority of the hair follicles were in telogen. In the sham-treated mice in group II after 6 weeks (Fig. 2a), the disruption of

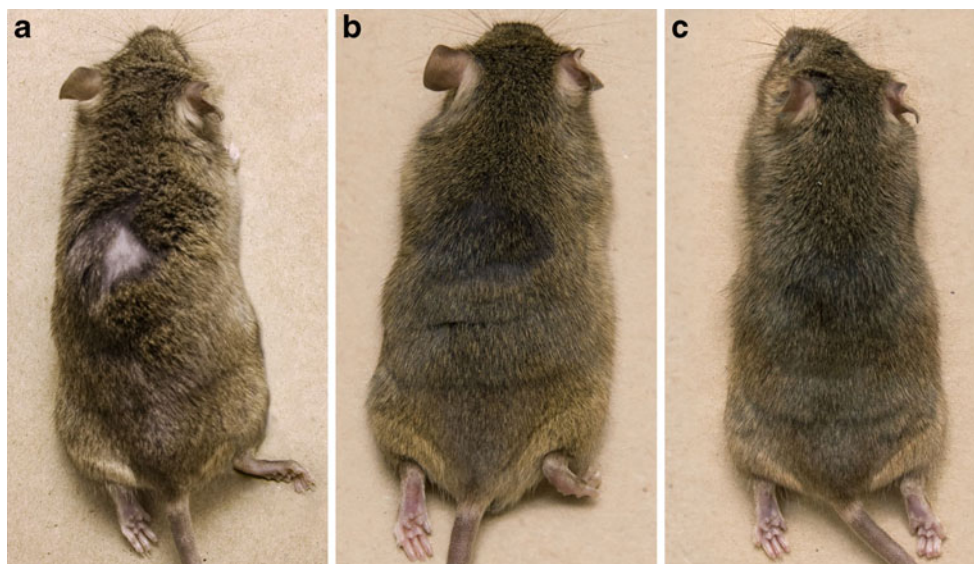
normal hair growth was apparent in the form of follicles without hair shafts, and the majority of the follicles were in the telogen phase, with the entire hair follicles located in the dermis. The sham-treated skin demonstrated reduced skin thickness and significantly reduced number of hair follicles.

Discussion

In this study, we explored the possibility of using the low-level laser to treat AA in a murine model. Laser therapy administered at dermatology clinics, such as the 308-nm excimer laser, has already been used for the treatment of AA with some success [33, 34]. Laser phototherapy has been shown to be effective in the treatment of androgenetic alopecia (AGA) with significantly greater increase in mean terminal hair density and improvements in overall hair regrowth in subjects treated with HairMax LaserComb® device at 26 weeks over baseline [32]. The LaserComb was cleared by the United States Food and Drug Administration (FDA) in January 2007 for marketing and promotion of hair regrowth in males with AGA who have Norwood Hamilton Classification of IIa-V and Fitzpatrick skin types I-IV.

The exact mechanism of action of LaserComb on hair regrowth is unclear. Laser phototherapy has been used for various purposes, and laser biostimulation has been shown to have prominent hair growth stimulatory effect in mice [35]. Additionally, cutaneous and other wound-regeneration-promoting effects of lasers have been demonstrated [36–40]. Repair and regeneration involve cell proliferation to a great extent, suggesting that the possible hair growth stimulatory effect of lasers is mediated through increased proliferative activity of follicular keratinocytes. The biostimulatory effect of low-level laser therapy has been studied on fibroblasts and shown to increase their proliferation even in proliferation-impaired streptozotocin-diabetic rats [41, 42]. It has been proposed that laser phototherapy with LaserComb device likely stimulates anagen re-entry in telogen hair follicles, increases rates of proliferation in active anagen hair follicles, prevents premature catagen development, and prolongs the duration of anagen phase. Further research is required to confirm any of these mechanisms [32]. The results of our study are consistent with these proposed mechanisms, as an increased number of hair follicles with majority in anagen phase were noted with a decreased inflammatory infiltrates in the mice treated with LaserComb as compared to the controls. These findings suggest that the LaserComb improves AA possibly by reducing the injurious effects of inflammatory attack on the hair follicles. Besides these, cellular (activation of dormant follicular stem cells and increased proliferation of hair matrix trichocytes), subcellular and molecular path-

Fig. 1 Effects of the Lexington HairMax LaserComb on hair regrowth in C3H/HeJ mice with alopecia areata. Shown are C3H/HeJ mice with heat-induced alopecia areata before (a) and after 2 weeks (b) or 6 weeks (c) of laser treatment



ways that may be involved in regrowth of hair in AA should be investigated [32].

Recently, attention has been drawn towards an uncommon but striking adverse effect of lasers being used for hair removal. It has been noticed that in some cases, an increase in hair density, color, or coarseness, or a combination of these, occurs at treated sites in the absence of any other known cause of hypertrichosis [43]. This phenomenon has been called paradoxical hypertrichosis. Its incidence has been reported to be from 0.6% [44] to 4.5% [45] to 10% [43, 46]. Different mechanisms have been proposed to explain this phenomenon. In one study, paradoxical hypertrichosis was attributed to the presence of polycystic ovarian syndrome in the five out of 49 females undergoing Intense Pulsed Light (IPL) laser treatment for facial hirsutism [43]. Another study suggested that subtherapeutic thermal injury to the follicular vasculature may affect follicular cycling in such a way that terminal hair growth rather than miniaturization is induced [44]. Although the heat produced by the laser is less than the temperature necessary for thermolysis of the hair follicle, this heat may be sufficient to induce follicular stem cell proliferation and differentiation by increasing the level of heat shock proteins (HSPs) such as HSP 27, which has been shown to play a

role in the regulation of cell growth and differentiation [47]. The subtherapeutic injury caused by the laser can result in the release of certain factors that can potentially increase follicular angiogenesis and affect hair cycling [48, 49]. These reports underlie the possibility that low-level lasers may be used to stimulate hair growth to treat hair disorders such as AA.

In the study investigating the efficacy and safety of the LaserComb in AGA, the device was found to be well tolerated and no serious adverse effects were noted [32]. Only four cases of mild paresthesia and four cases of mild urticaria among a total of 52 patients (excluding ten subjects from the HairMax treated group, who terminated prematurely and were not included in the primary analysis of effectiveness) were possibly device-related adverse effects, but no statistical difference between the study groups was observed.

Our study is the first to investigate the efficacy of HairMax LaserComb for the treatment of AA. We used a mouse model with hair loss previously shown to mimic AA both clinically and histologically [31], and observed marked hair regrowth in LaserComb-treated mice compared with sham-treated mice. While hair regrowth was first observed 2 weeks later, the follicles were either still in anagen or in catagen, indicating that there is a much longer growth phase [50]. If

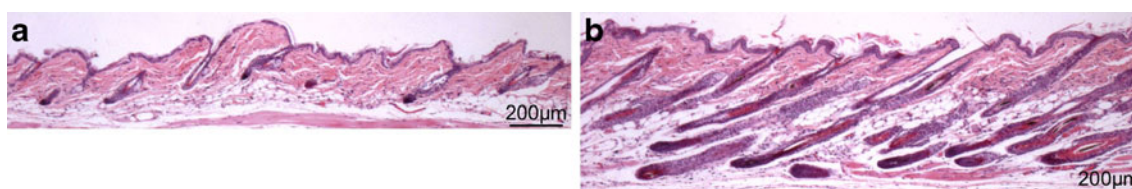


Fig. 2 Hematoxylin and eosin staining of skin biopsy sections from C3H/HeJ mice with heat-induced alopecia areata after 6 weeks of sham treatment (with laser off) (a) and LaserComb treatment (b)

similar results are observed in clinical trials, the LaserComb may be a suitable device for treating AA.

Acknowledgments We are grateful for the generous support from Locks of Love to Dr. J.J.Jimenez. The HairMax LaserCombs were provided by Lexington International, LLC (Boca Raton, FL). Dr. T.C. Wikramanayake is supported by a Career Development Award (AR050487) from NIH/NIAMS.

References

- Wasserman D, Guzman-Sanchez DA, Scott K, McMichael A (2007) Alopecia areata. *Int J Dermatol* 46:121–131
- Lew BL, Shin MK, Sim WY (2009) Acute diffuse and total alopecia: a new subtype of alopecia areata with a favorable prognosis. *J Am Acad Dermatol* 60:85–93
- Tosti A, Bellavista S, Iorizzo M (2006) Alopecia areata: a long-term follow-up study of 191 patients. *J Am Acad Dermatol* 55:438–441
- Safavi K (1992) Prevalence of alopecia areata in the First National Health and Nutrition Examination Survey. *Arch Dermatol* 128:702
- Safavi KH, Muller SA, Suman VJ, Moshell AN, Melton LJ 3rd (1995) Incidence of alopecia areata in Olmsted County, Minnesota, 1975 through 1989. *Mayo Clin Proc* 70:628–633
- Price VH (2003) Therapy of alopecia areata: on the cusp and in the future. *J Invest Dermatol Symp Proc* 8:207–211
- Madani S, Shapiro J (2000) Alopecia areata update. *J Am Acad Dermatol* 42:549–566
- de Berker DAR, Messenger AG, Sinclair RD (2004) Disorders of hair. In: Burns DA, Breathnach SM, Cox N, Griffiths CE (eds) *Rook's textbook of dermatology* Vol. 4, 7th edn. Wiley-Blackwell, Oxford, pp 63.1–63.120
- Tosti A, Duque-Estrada B (2010) Dermoscopy in hair disorders. *J Egypt Women Dermatol Soc* 7:1
- Weedon D (2002) Diseases of cutaneous appendages. In: Weedon D (ed) *Weedon's skin pathology*. Churchill Livingstone, London
- Whiting DA (2003) Histopathologic features of alopecia areata: a new look. *Arch Dermatol* 139:1555–1559
- Sperling LC (2003) Alopecia areata. In: Sperling LC (ed) *An atlas of hair pathology with clinical correlations*, 1st edn. Parthenon Publishing, New York, pp 109–138
- Ahmed Z, Banik RL, Paul HK, Jaigirdar QH, Begum F, Chowdhury SA (2010) Histopathological changes in different stages of alopecia areata. *Mymensingh Med J* 19(1):100–105
- Paus R, Nickoloff BJ, Ito TA (2005) “Hairy” privilege. *Trends Immunol* 26:32–40
- Harrist TJ, Ruiter DJ, Mihm MC, Bhan AK (1983) Distribution of major histocompatibility antigens in normal skin. *Br J Dermatol* 109:623–633
- Christoph T, Müller-Röver S, Audring H, Tobin DJ, Hermes B, Cotsarelis G, Rückert R, Paus R (2000) The human hair follicle immune system: cellular composition and immune privilege. *Br J Dermatol* 142(5):862–873
- Ito T, Saathoff M, Nickoloff BJ, Takigawa M, Paus R (2005) Novel aspects of hair follicle immune privilege and their relevance to alopecia areata [abstract]. *J Invest Dermatol* 124(Suppl):A103
- Paus R, Christoph T, Müller-Röver S (1999) Immunology of the hair follicle: a short journey into terra incognita. *J Invest Dermatol Symp Proc* 4:226–234
- Deeths MJ, Endrizzi BT, Irvin ML, Steiner LP, Ericson ME, Hordinsky MK (2006) Phenotypic analysis of T-cells in extensive alopecia areata scalp suggests partial tolerance. *J Invest Dermatol* 126(2):366–373, PubMed PMID: 16374469
- Galbraith GM, Palesch Y, Gore EA, Pandey JP (1999) Contribution of interleukin 1beta and KM loci to alopecia areata. *Hum Hered* 49(2):85–89, PubMed PMID: 10077728
- Kim HS, Cho DH, Kim HJ, Lee JY, Cho BK, Park HJ (2006) Immunoreactivity of corticotropin-releasing hormone, adrenocorticotropic hormone and alpha-melanocyte-stimulating hormone in alopecia areata. *Exp Dermatol* 15(7):515–522, PubMed PMID: 16761960
- Hoffmann R (1999) The potential role of cytokines and T cells in alopecia areata. *J Invest Dermatol Symp Proc* 4(3):235–238
- Gilhar A, Ullmann Y, Berkutzi T, Assy B, Kalish RS (1998) Autoimmune hair loss (alopecia areata) transferred by T lymphocytes to human scalp explants on SCID mice. *J Clin Invest* 101(1):62–67
- Shimizu T, Hizawa N, Honda A et al (2005) Promoter region polymorphism of macrophage migration inhibitory factor is string risk factor for young onset of extensive alopecia areata. *Genes and Immunity* 6(4):285–289
- Messenger AG, Slater DN, Bleehen SS (1986) Alopecia areata: alterations in the hair growth cycle and correlation with the follicular pathology. *Br J Dermatol* 114:337–347
- Petukhova L, Duvic M, Hordinsky M, Norris D, Price V, Shimomura Y, Kim H, Singh P, Lee A, Chen WV, Meyer KC, Paus R, Jahoda CA, Amos CI, Gregersen PK, Christiano AM (2010) Genome-wide association study in alopecia areata implicates both innate and adaptive immunity. *Nature* 466(7302):113–117
- Sundberg JP, Cordy WR, King LE Jr (1994) Alopecia areata in aging C3H/HeJ mice. *J Invest Dermatol* 102:847–856
- Sun J, Silva KA, McElwee KJ, King LE Jr, Sundberg JP (2008) The C3H/HeJ mouse and DEBR rat models for alopecia areata: review of preclinical drug screening approaches and results. *Exp Dermatol* 17:793–805
- McElwee KJ, Boggess D, Olivry T et al (1998) Comparison of alopecia areata in human and nonhuman mammalian species. *Pathobiology* 66:90–107
- McElwee KJ, Hoffmann R (2002) Alopecia areata - animal models. *Clin Exp Dermatol* 27:410–417
- Wikramanayake TC, Alvarez-Connelly E, Simon J, Mauro LM, Guzman J, Elgart G, Schachner LA, Chen J, Plano LR, Jimenez JJ (2010) Heat treatment increases the incidence of alopecia areata in the C3H/HeJ mouse model. *Cell Stress Chaperones* 15(6):985–991
- Leavitt M, Charles G, Heyman E, Michaels D (2009) HairMax LaserComb laser phototherapy device in the treatment of male androgenetic alopecia: a randomized, double-blind, sham device-controlled, multicentre trial. *Clin Drug Investig* 29(5):283–292
- Al-Mutairi N (2007) 308-nm excimer laser for the treatment of alopecia areata. *Dermatol Surg* 33(12):1483–1487
- Al-Mutairi N (2009) 308-nm excimer laser for the treatment of alopecia areata in children. *Pediatr Dermatol* 26(5):547–550
- Mester E, Szende B, Gärtner P (1968) The effect of laser beams on the growth of hair in mice. *Radiobiol Radiother (Berl)* 9(5):621–626
- Bibikova A, Oron U (1993) Promotion of muscle regeneration in the toad (*Bufo viridis*) gastrocnemius muscle by low-energy laser irradiation. *Anat Rec* 235:374–380
- Pinheiro AL, Gerbi ME (2006) Photoengineering of bone repair processes. *Photomed Laser Surg* 24:169–178
- Liu X, Lyon R, Meier HT et al (2007) Effect of lower-level laser therapy on rabbit tibial fracture. *Photomed Laser Surg* 25:487–494
- Yu W, Naim JO, Lanzafam RJ (1997) Effects of photostimulation on wound healing in diabetic mice. *Lasers Surg Med* 20:56–63
- de Carvalho PT, Mazzer N, dos Reis FA et al (2006) Analysis of the influence of low-power He-Ne laser on the healing of skin wounds in diabetic and non-diabetic rats. *Acta Cir Bras* 21:177–183

41. Pal G, Dutta A, Mitra K et al (2007) Effect of low-intensity laser interaction with human skin fibroblast cells using fiber-optic nanoprobes. *J Photochem Photobiol* 86:252–256
42. Mirzaei M, Bayat M, Mosafa N et al (2007) Effect of low-level laser therapy on skin fibroblasts of streptozotocin-diabetic rats. *Photomed Laser Surg* 25:519–525
43. Moreno-Arias G, Castelo-Branco C, Ferrando J (2002) Paradoxical effect after IPL photoepilation. *Dermatol Surg* 28:1013–1016
44. Alajlan A, Shapiro J, Rivers JK et al (2005) Paradoxical hypertrichosis after laser epilation. *J Am Acad Dermatol* 53:85–88
45. Kontoes P, Vlachos S, Konstantinos M et al (2006) Hair induction after laser-assisted hair removal and its treatment. *J Am Acad Dermatol* 54:64–67
46. Desai S, Mahmoud BH, Bhatia AC, Hamzavi IH (2010) Paradoxical hypertrichosis after laser therapy: a review. *Dermatol Surg* 36(3):291–298, Epub 2010 Jan 19. Review
47. Bouzari N, Firooz AR (2006) Lasers may induce terminal hair growth. *Dermatol Surg* 32:460
48. Bukhari IA (2006) Pili bigemini and terminal hair growth induced by low-fluence alexandrite laser hair removal. *J Cutan Med Surg* 10:96–98
49. Lolis MS, Marmur ES (2006) Paradoxical effects of hair removal systems: a review. *J Cosmet Dermatol* 5:274–246
50. Müller-Röver S, Handjiski B, van der Veen C, Eichmüller S, Foitzik K, McKay IA, Stenn KS, Paus R (2001) A comprehensive guide for the accurate classification of murine hair follicles in distinct hair cycle stages. *J Invest Dermatol* 117(1):3–15